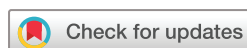

Inguinal-related groin pain in athletes: a pathological potpourri

Zarko Vuckovic,¹ Andreas Serner ,¹ Willem M P Heijboer ,^{1,2,3}
Adam Weir ^{1,4}

To cite: Vuckovic Z, Serner A, Heijboer WMP, *et al.* Inguinal-related groin pain in athletes: a pathological potpourri. *BMJ Open Sport & Exercise Medicine* 2022;**8**:e001387. doi:10.1136/bmjsem-2022-001387

Accepted 22 August 2022



© Author(s) (or their employer(s)) 2022. Re-use permitted under CC BY-NC. No commercial re-use. See rights and permissions. Published by BMJ.

¹Sports Groin Pain Centre, Aspetar Orthopaedic and Sports Medicine Hospital, Doha, Qatar

²Amsterdam UMC location University of Amsterdam, Academic Center for Evidence Based Medicine, Amsterdam IOC Center ACHSS, Meibergdreef 9, Amsterdam, The Netherlands

³Amsterdam Movement Sciences, Sports, Amsterdam, The Netherlands

⁴Department of Orthopaedics and Sports Medicine, Erasmus MC University Medical Centre, Rotterdam, The Netherlands

Correspondence to

Dr Zarko Vuckovic;
Zarko.vuckovic@aspetar.com

Athletes who have pain in the inguinal canal region with no actual hernia present as a common challenge in clinical practice. While the differential diagnosis of groin pain is broad, our editorial focuses on musculoskeletal causes.

A survey of 23 international groin pain experts using the case of a male football player with pain in the inguinal region was performed in 2014. The experts were asked which term they would use to describe the diagnosis.¹ The 23 experts used 22 different terms, including inguinal-related groin pain, sportsman's hernia, incipient hernia, inguinal disruption, posterior wall weakness, Gilmore's groin and core muscle injury to name but a few.

Following a subsequent expert consensus meeting on terminology and definitions, this group agreed on 'inguinal-related groin pain' as the preferred term.² While there is debate about the appropriate terminology, there is even more uncertainty surrounding the underlying pathology. There are numerous hypotheses on the pathology of inguinal-related groin pain. This 'pathological potpourri' causes confusion in the literature and in clinical practice.

Some of the different theories reported in the literature are listed in [table 1](#). We have included an illustration with some of the most prominent theories ([figure 1](#)).

SINGLE UNIFYING THEORY OF EVERYTHING?

So how should we interpret all these different hypotheses?

It is tempting to turn it into a contest and declare a winner. There is a realistic probability that there are different causes between individuals. Trying to prove a single unifying underlying pathology is likely to be fruitless. Most theories are based on two main ideas or combinations of these ideas:

1. Nerve irritation (including posterior wall bulge causing compression or entrapment) of the ilioinguinal/iliohypogastric/

genitofemoral nerve(s) in the inguinal region.

2. Musculoskeletal pathology (including aponeurotic tears and inguinal ligament enthesopathy).

These two groups may overlap through overload of several anatomical structures in the inguinal canal. Anatomical variations of the cutaneous branches of the ilioinguinal nerve and genital branch of the genitofemoral nerve should also be considered as a potential explanation for variations in pain distribution.³

Medical teams treating groin pain continue to see patients with inguinal-related groin pain who have different clinical presentations. Some patients present with brief pain only related to certain explosive movements, while others have pain for weeks or months following sporting activity. Patients also report different pain types (electric, burning, stabbing, etc). There may be tenderness of different structures during examination, while others are pain free in the clinic, and only precise history or sports-specific testing combined with appropriate imaging if needed (such as excluding inguinal hernia), leads us to the diagnosis.

MULTIPLE THEORIES CAN EXPLAIN DIFFERENT TREATMENT CHOICES

The varying theories on pathoetiology seem to have influenced treatments. Currently, the literature on inguinal-related groin pain is heavily focused on surgical treatment, with multiple options reported. Surgical approaches can be broadly categorised into two groups that mirror some of the proposed pathologies:

1. Anterior open mesh or non-mesh reinforcement of the posterior wall, with or without neurectomy.
2. Posterior endoscopic mesh reinforcement of the posterior wall, with or without inguinal ligament 'release'.

A recent multicentre randomised controlled trial comparing open and endoscopic repair

Table 1 Theories on the underlying pathology of inguinal-related groin pain in athletes in chronological order divided into theories on nerve irritation and musculoskeletal (MSK) injuries

Nerve irritation theories	Year and authors
Nerve entrapment Peripheral nerves may become entrapped after direct trauma or inflammatory conditions. The ilioinguinal nerve transmits sensation from the proximal part of the penis and the base of the scrotum. These sensations may be elicited by intensive abdominal muscle training leading to entrapment of the nerve, where it goes through the different layers of the abdominal muscles ⁶	1980; Renstrom and Peterson ⁶
Posterior abdominal wall weakness/bulge ('incipient hernia'/'sports hernia') A. Insufficient strength of the fascia transversalis to withstand the repeated high intra-abdominal pressure generated by sports activities ⁷ B. Distension of the peritoneum or stretching of the ilioinguinal nerve ⁸ C. Bulge in the posterior inguinal wall consistent with an incipient direct inguinal hernia ⁹ D. Distension of the posterior inguinal canal wall musculature, suggested by the site of maximal tenderness, painful cough impulse and operative findings (an early type of direct hernia/sports hernia) ¹¹ E. Nerve irritation of the ilioinguinal and the genital branch of the genitofemoral nerve within the inguinal canal caused by a 'sports hernia'. Additionally, possible entrapment neuropathy ¹² F. A circumscribed weakness of the inguinal canal posterior wall causing a bulge compressing the genital branch of genitofemoral nerve during straining. Additionally, as the canal is widened, the rectus muscle is medially and cranially retracted. This retraction causes increased tension, leading to pubalgia ¹³ G. During muscular contraction of the abdominal wall, the conjoint tendon lowers and closes the deep inguinal ring like 'a curtain', decreasing its diameter. A high insertion of the conjoint tendon leaves the inguinal ring wider and uncovered, thus more exposed to repeated sports-related microtrauma, in particular, the protrusion of preperitoneal fat in the deep inguinal orifice ¹⁴	A. 1985; Smedberg <i>et al</i> ⁷ B. 1989; Gullmo ⁸ C. 1992; Malycha and Lovell ⁹ D. 1991; Polglase <i>et al</i> ¹⁰ E. 1993; Hackney ¹¹ F. 1999; Akita <i>et al</i> ¹² G. 2010; Muschaweck and Berger ¹³ H. 2019; Bou Antoun <i>et al</i> ¹⁴
Tear of the external oblique Nerve irritation caused by single or multiple tears in the external oblique aponeurosis at the site of the emergence of neurovascular bundles containing the terminal branches of the iliohypogastric nerve ^{15 16}	1995; Williams and Foster ¹⁵ 1999; Ziprin <i>et al</i> ¹⁶
Musculoskeletal pathology theories	Year and authors
Muscle imbalance causing pain and changes at pubic bones Muscle imbalance at the level of pubic symphysis due to weak anterior abdominal wall and hypertrophic lower limb muscles causing an excessive functional overload of muscular and tendon insertions on the pubic bone ¹⁷	1987; Nesovic ¹⁷
Severe musculotendinous injury Severe musculotendinous injury, such as a torn external oblique aponeurosis or conjoint tendon torn from the pubic tubercle. Dehiscence between conjoint tendon and inguinal ligament ^{18 19}	1991; Gilmore ¹⁸ 1998; Gilmore ¹⁹
Pubic joint concept Pain is due to an insertional shearing injury of the muscular attachments at the pubis, mainly inguinal canal, rectus abdominis and adductor muscles, causing pain at the pubic symphysis ^{20 21}	2000; Meyers <i>et al</i> ²⁰ 2012; Meyers <i>et al</i> ²¹
Inguinal ligament enthesopathy Inguinal ligament enthesopathy at the pubic tubercle. This is due to excessive stress during lateral abdominal muscle contraction. The abdominal core muscles play a pivotal role in the cause of pain as their forces are transmitted through the inguinal ligament onto the pubic tubercle ²²	2008; Lloyd <i>et al</i> ²³ 2009; Mann <i>et al</i> ²⁴ 2017; Rennie and Lloyd ²²

did not find clinically relevant differences in outcomes.⁴ Our previous systematic review on the management of groin pain in athletes found both a lack of high-quality studies, and an association where studies with worse methods showed better results.⁵

HOW DO WE ADVANCE?

We recognise that 'inguinal-related groin pain' is a vague term. However, if we embrace the current

variation in pathological explanations, then we cannot support any further distinction in exact pathology. We, therefore, currently continue to recommend using 'inguinal-related groin pain'.

To advance the field, we need a broad approach and embrace that there is uncertainty. It is a challenge to try and test the multiple hypotheses. We need to develop an encompassing approach, including:

1. Reliable tests of the suggested pathologies

1. Posterior wall bulge
2. Ilioinguinal nerve adhesions
3. Ilioinguinal or iliohypogastric nerve entrapment
4. Tears in external oblique aponeurosis
5. Enthesopathy at inguinal ligament insertion

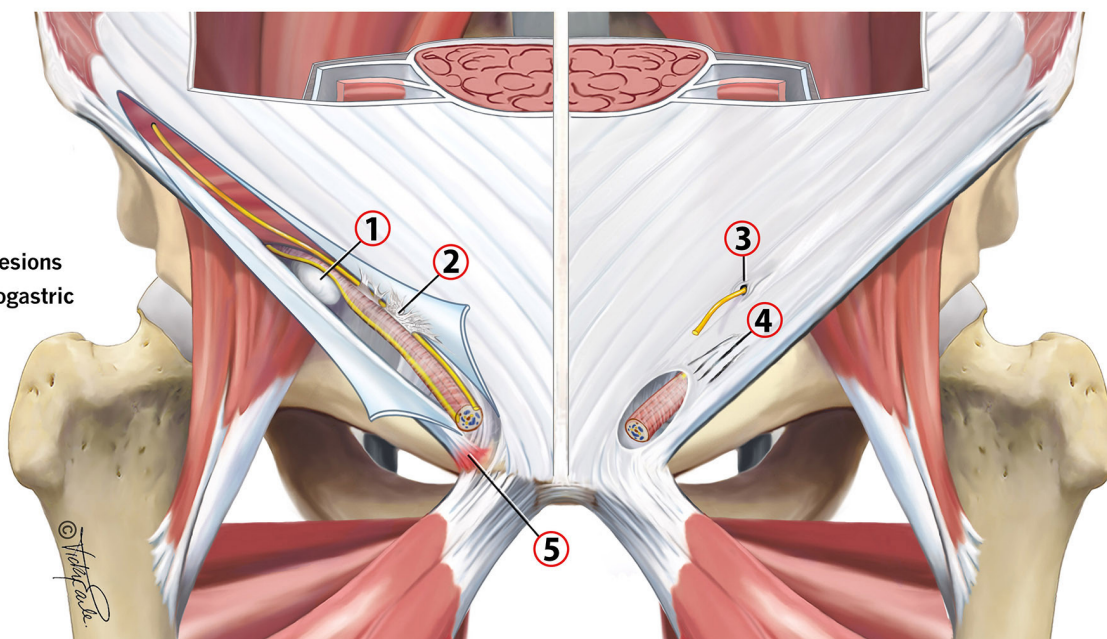


Figure 1 Potential causes of inguinal pain in athletes.

2. Knowledge of normal findings in athletic populations
3. Acceptance that various pathologies may co-exist and are not mutually exclusive
4. Understanding that there is significant variation between individuals in anatomy and nerve distribution.
5. Open minds.

At present, these are lacking. It will be a complex and time-consuming process to sift through the various potpourri ingredients. We are more likely to progress if we collaborate on projects to improve study power and share ideas. It is important to recognise that the focus here is on underlying pathology, but as with all musculo-skeletal pain conditions the biopsychosocial factors will play their role too. This is also something that needs to be explored further.

In summary, simplistic thinking about single pathologies in inguinal-related groin pain is preventing progress. Acknowledging the current pathological potpourri will allow progress and enable more encompassing approaches.

Twitter Zarko Vuckovic @zarkov_d, Andreas Serner @aserner, Willem M P Heijboer @WillemHeijboer and Adam Weir @adamweirsports

Acknowledgements We thank Vicky Earle for her collaboration on the illustration.

Contributors ZV, AS, WMPH and AW: conceptualisation, writing—original draft, writing—review and editing, visualisation.

Funding Illustration and open access for the editorial was funded by Aspetar - Qatar Orthopaedic and Sports Medicine Hospital.

Competing interests None declared.

Patient consent for publication Not applicable.

Ethics approval Not applicable.

Provenance and peer review Not commissioned; externally peer reviewed.

Open access This is an open access article distributed in accordance with the Creative Commons Attribution Non Commercial (CC BY-NC 4.0) license, which

permits others to distribute, remix, adapt, build upon this work non-commercially, and license their derivative works on different terms, provided the original work is properly cited, appropriate credit is given, any changes made indicated, and the use is non-commercial. See: <http://creativecommons.org/licenses/by-nc/4.0/>.

ORCID iDs

Andreas Serner <http://orcid.org/0000-0003-4308-901X>

Willem M P Heijboer <http://orcid.org/0000-0002-5723-8445>

Adam Weir <http://orcid.org/0000-0003-0861-662X>

REFERENCES

- 1 Weir A, Hölmich P, Schache AG, *et al.* Terminology and definitions on groin pain in athletes: building agreement using a short Delphi method. *Br J Sports Med* 2015;49:825–7.
- 2 Weir A, Brukner P, Delahunt E, *et al.* Doha agreement meeting on terminology and definitions in groin pain in athletes. *Br J Sports Med* 2015;49:768–74.
- 3 Ndiaye A, Diop M, Ndoye JM, *et al.* Anatomical basis of neuropathies and damage to the ilioinguinal nerve during repairs of groin hernias. (about 100 dissections). *Surg Radiol Anat* 2007;29:675–81.
- 4 Sheen AJ, Montgomery A, Simon T, *et al.* Randomized clinical trial of open suture repair versus totally extraperitoneal repair for treatment of sportsman's hernia. *Br J Surg* 2019;106:837–44.
- 5 Serner A, van Eijck CH, Beumer BR, *et al.* Study quality on groin injury management remains low: a systematic review on treatment of groin pain in athletes. *Br J Sports Med* 2015;49:813.
- 6 Renström P, Peterson L. Groin injuries in athletes. *Br J Sports Med* 1980;14:30–6.
- 7 Smedberg SG, Broome AE, Gullmo A, *et al.* Herniography in athletes with groin pain. *Am J Surg* 1985;149:378–82.
- 8 Gullmo A. Herniography. *World J Surg* 1989;13:560–8.
- 9 Malycha P, Lovell G. Inguinal surgery in athletes with chronic groin pain: the 'sportsman's' hernia. *Aust N Z J Surg* 1992;62:123–5.
- 10 Polglase AL, Frydman GM, Farmer KC. Inguinal surgery for debilitating chronic groin pain in athletes. *Med J Aust* 1991;155:674–7.
- 11 Hackney RG. The sports hernia: a cause of chronic groin pain. *Br J Sports Med* 1993;27:58–62.
- 12 Akita K, Niga S, Yamato Y, *et al.* Anatomic basis of chronic groin pain with special reference to sports hernia. *Surg Radiol Anat* 1999;21:1–5.
- 13 Muschawec U, Berger L. Minimal repair technique of sportsmen's groin: an innovative open-suture repair to treat chronic inguinal pain. *Hernia* 2010;14:27–33.

- 14 Bou Antoun M, Ronot M, Crombe A, *et al.* High insertion of conjoint tendon is associated with inguinal-related groin pain: a MRI study. *Eur Radiol* 2020;30:1517–24.
- 15 Williams P, Foster ME. 'Gilmore's groin'-or is it? *Br J Sports Med* 1995;29:206–8.
- 16 Ziprin P, Williams P, Foster ME. External oblique aponeurosis nerve entrapment as a cause of groin pain in the athlete: external oblique aponeurosis nerve entrapment. *Br J Surg* 1999;86:566–8.
- 17 Nesovic B. Bolni sindrom simfeze kod sportista i mogucnosti njegovog lecenja. In: *Povrede u sportu i njihovo lecenje. Zdravstvena kimosija SFKJ*, 1987.
- 18 Gilmore OJA. Gilmore's groin: ten years experience of groin disruption - a previously unsolved problem in sportsmen. *Sports Med Soft Tissue Trauma* 1991;1:12–14.
- 19 Gilmore J. Groin pain in the soccer athlete: fact, fiction, and treatment. *Clin Sports Med* 1998;17:787–93.
- 20 Meyers WC, Foley DP, Garrett WE, *et al.* Management of severe lower abdominal or inguinal pain in high-performance athletes. *Am J Sports Med* 2000;28:2–8.
- 21 Meyers WC, Yoo E, Devon ON, *et al.* Understanding "Sports Hernia" (Athletic Pubalgia): The Anatomic and Pathophysiologic Basis for Abdominal and Groin Pain in Athletes. *Oper Tech Sports Med* 2012;20:33–45.
- 22 Rennie WJ, Lloyd DM. Sportsman's groin: the inguinal ligament and the Lloyd technique. *J Belg Soc Radiol* 2017;101:16.
- 23 Lloyd DM, Sutton CD, Altafa A, *et al.* Laparoscopic inguinal ligament tenotomy and mesh reinforcement of the anterior abdominal wall: a new approach for the management of chronic groin pain. *Surg Laparosc Endosc Percutan Tech* 2008;18:363–8.
- 24 Mann CD, Sutton CD, Garcea G, *et al.* The inguinal release procedure for groin pain: initial experience in 73 sportsmen/women. *Br J Sports Med* 2009;43:579–83.